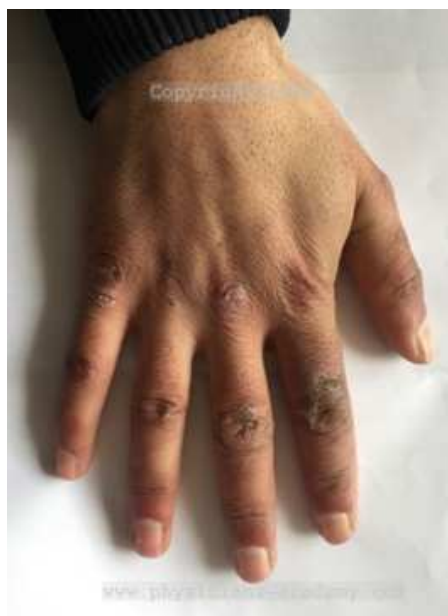



POTM
Physicians Academy
January 2018

JANUARY 2018
Picture of The Month
Sarosh Ahmed Khan, MD; FACP

A 25 years old male presented with complaints of pain and eroded skin of the fingers of his right hand. He gives history of similar problem during winters in the last two years only. He is a computer technician working in a Cyber Café. What is your diagnosis?



Send your answer to us on Rapid Response.

Contributed by: Dr. Sarosh A. Khan is Senior Consultant, Internal Medicine and Director, Naseem Medical Center, Baghe-Mehtab, Srinagar, Kashmir, India. Pin: 190019. He is the Editor in Chief of Physicians Academy. Affiliations: Governing Council Member of American College of Physicians (India Chapter) from 2014-2017. Email: drsarosh@gmail.com

Answer to last month's POTM December 2017

A 21 year young female presented with complaints of occasional palpitations. Clinically she was of average built with no anemia, cyanosis or jaundice. Pulse 80/min and Blood Pressure of 110/70 mmHg. Peripheral pulses were normal. Chest and abdomen were clinically normal. Cardiac examination revealed normal S1 and S2. There is a systolic murmur II/VI in left sternal border. Transthoracic Echocardiography reveals (see pics). What is your diagnosis?

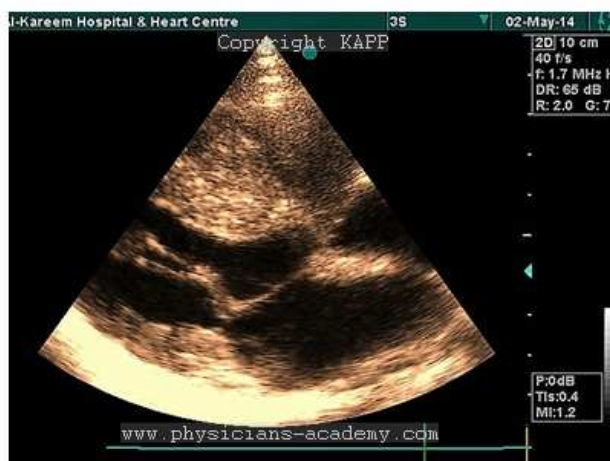

Fig. 1. 2D-Echo. Parasternal Long axis View.

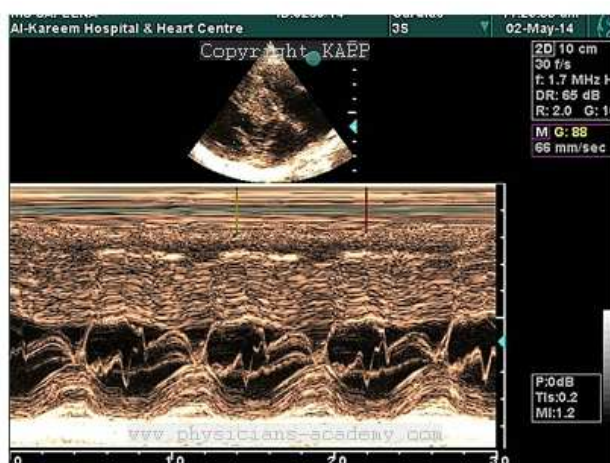


Fig. 2. M-Mode Echo

The Correct Answer

POTM December 2017 is typical picture of Hypertrophic Cardiomyopathy (HCM). Two findings diagnostic of HCM in this picture are 1) Asymmetrical septal hypertrophy -ASH and Systolic anterior Motion of anterior mitral leaflet -SAM of AML. (Fig. 1 and 2).

For details of this topic see the article by same author in the present issue of PA.

Here is the link:

<http://www.physicians-academy.com/CD-hypertrophic-cardiomyopathy-873.aspx>

Contributed by: Dr. Mehraj Ud Din Shah, MD; DM; FICC; FESC; FACC is Senior Consultant Cardiologist at Al-Kareem Cardiac Center, Jawahar Nagar, Srinagar, Kashmir, India. Email: drmerajuddin@gmail.com

Dear Readers: Would you like to contribute to this page? Send us your contribution (photograph and 1-3 paragraphs about it) by email to drsarosh@gmail.com